

DOI: <http://doi.org/10.32792/utq.jceps.10.01.01>

Evaluation of amyloid protein expression in a neurodegenerative rat model impairs memory abilities by *Ocimum basilicum* extract

Marwa Ammer Shalan¹

Layla Alhasan¹

layla.alhasan@utq.edu.iq

Biology Department, Education College for Pure Sciences, Thiqr University, Iraq

Received 14/11/2023,

Accepted 20/11/2023,

Published 1/12/2023



This work is licensed under a [Creative Commons Attribution 4.0 International License](https://creativecommons.org/licenses/by/4.0/).

Abstract

The main objective of this study was to evaluate of the neuroprotective potential effect of *Ocimum basilicum* on amyloid protein expression in rat induced Alzheimer's disease. Fifty rats were divided into five groups (ten rats each). Rats were treated orally with AlCl₃ to induced AD. Group I (control group). Group II (AD group): supplemented orally with AlCl₃ (17mg/kg/day) for four weeks. Group III (*O. b* /AD group) supplemented concomitantly with oral rivastigmine (3 mg/kg /day). Group IV (*O. b*/AD group) supplemented concomitantly with oral OB (250mg/kg/day) and Group V (*O. b*/AD group) supplemented concomitantly with oral *O. b* (500 mg/kg/day). The results showed that deposition of amyloid protein expression was increased in positive group (AD induced rats) . Histological changes were observed in brain tissues of AD rats. Minor deposition of amyloid protein (arrow) in cerebral parenchyma was observed. However, the high dosing of the plant leaves extract (500 mg/kg) was more powerful than the low treatment with low dose (250 mg/kg) by decreasing accumulation of amyloid protein expression. The results suggest that *Ocimum basilicum* can relieve symptoms and prevent the progression of AD severity by improving memory function. It can be concluded that OB leaves were alleviated the memory impairment and learning abilities due to antioxidants activity of flavonoids, tannins and terpenoids

Keywords: *Amyloid protein, immunohistochemistry, Ocimum basilicum, memory abilities*

Introduction

Alzheimer's disease (AD) is a neurodegenerative condition marked by irreversible cognitive and memory loss (John et al., 2022). AD is also the 5th leading cause of death in elderly patients that are 65 age and years of

The disorder is characterized by a wide range of symptoms, including cognitive dysfunction, behavioral disorders, memory and language abnormalities (Yuan , et al. 2019), A significant social and financial burden is placed on society as a result of its incapacitating character (Mahdy ,et al. 2012). The emergence of AD and its pathophysiology have been linked to a wide variety of biological processes. A lot of

research has been done so far in an effort to explain the process and prospective therapeutic objectives in the fight against AD. Reactive oxygen species (ROS) accumulate within cells as a result of oxidative stress, which in turn causes protein, lipid, and DNA oxidations that harm cells. ROS levels are correlated with senility and higher amyloid-deposition plaque development, two features of the AD brain (Mehan S, et. al. 2015). Beta amyloid deposits are the main cause of AD and it is a consider a product of processing error of precursor protein APP in the brain .the accumulate clusters of AB –proteins are Amyloid plagues. The amyloid plagues in the brain provoke the destruction of neuronal cell and leads to AD (Bui & Nguyen,et al. 2017).

Beta amyloid accumulation and ROS levels inhibit by using natural antioxidants to treat AD. Thus, there is a high demand for discovering new therapies of natural origin gained from medicinal plants for protection, slowing down or halting progression of AD disease in its primary stages. In that context, *Ocimum basilicum* was used in this study as a herbal medicines which considered harmless agents and used as alternative and complementary therapeutics. *Ocimum basilicum* L. (*O. basilicum*) or basil is medicinal plant and a significant essential oil crop which belongs to the Lamiaceae family. The present study was conducted to investigate the effects of *Ocimum basilicum* L. (OB) extract on memory impairment and oxidative damage which induced by accumulation AB in rat model, that could be making it potential agent for AD treatment

Methodology

Preparation of *Ocimum basilicum*

Leaves of *Ocimum basilicum* were collected from local Thiqar(Al- shatraa) farm . The botanical identification was kindly identified by Dr. Yaas K.Abbas (Biology department, Education college for Pure Sciences, Thiqar University). After collection, the plant leafs were dried in oven under 60oC and then grounded to fine powder . Preparation of aqueous plant leaves were done by soaking 100 gm of plant extract powder in 100 ml sterile boiled water for 7 days at 25°C with interim shaking. After that, the mixture was centrifuged at 3000 rpm for few minutes and the supernatant was evaporated by rotary evaporator. The methanol (10 ml) was added to plant extract, followed by centrifugation and extract was evaporated.

Induction of Alzheimer’s disease

Rats were inducted with Alzheimer’s disease orally administration using AlCl₃ dissolved in distilled water in a dose of 17 mg/kg b. wt. daily for one month .

Experimental Design

The present study was conducted on 50 adult male Sprague Dawley rats weighing from 200 _+50 g obtained from the Animal House Colony of the Animal house, College of Science, Thi-Qar University, Iraq. The animals were maintained on standard laboratory diet and water. After one week, the animals were housed in standard cages at room temperature with artificially illuminated (12 h dark/light cycle) room free from chemical contamination. All animals received human care and use according to the guidelines for Animal Experiments which were approved by the Ethical Committee of Medical Research,

National Research Centre, Iraq (No 63438/23/9). The animals used were divided into five groups (10 rats each) as follows: The animals used were divided into five groups (10 rats each) as follows:

Group I: Rats (negative group) were received normal diet and tap water to end of experiment.

Group II: Rats (positive group) obtained 17 mg/kg orally and normal diet for one month.

Group III: Rats obtained 17 mg/kg orally and treated with 3 mg/kg rivastigmine for one month (Ghoneim ,et al. 2015).

Group IV: Rats obtained 17 mg/kg orally and treated with 250 mg/ml *Ocimum basilicum* for one month.

Group V Rats obtained 17 mg/kg orally and treated by 500 mg/ml *Ocimum basilicum* for one month.

Sample Collection

At the end of experiment, rats were kept fasting for half day. Blood samples were collected using the orbital sinus technique of Sandford for further analysis. Rats were then decapitated, their entire brains were quickly dissected, thoroughly washed with isotonic buffer, dried, and subsequently for immediately frozen at -80 to measure of tau protein. Amyloid scoring system depended on criteria ranged from 0 to 3 (0 = absent, 1 = <25%, 2 = 25–50% and 3 = >50%) of examined tissue sections (Hoelbeek, et al.2021).

Histopathology

Brain samples were obtained, fixed in 10% formalin for 48 hours, and then changed to a new formalin solution after 24 hours.

An automated tissue processor (Histo-Line ATP700, Italy) was used to slice the brain samples to a thickness of 0.5 mm, and they were then placed in plastic cassettes for the dehydration and clearing process before being routinely embedded in paraffin using a tissue embedding system (HESTION TEC2800-C, China).

The brain samples were subsequently cut and sectioned at 4 μ m thickness using semiautomatic microtome (Histo-Line MRS3500, Italy).

Then the brain pieces were placed carefully in water bath (FALC BI, Italy) and mounted on glass slides using a hot plate (K&K HYSH11, Korea).

Then, brain sections were stained with two stains: Hematoxylin and Eosin stain.

Statistical Analysis

All data were performed at least three triplicate and expressed as average value \pm standard deviation. Multiple data were analyzed using one way analysis of variance (ANOVA) using graphed prism (version 9). data is considered statistically significant when $p < 0.001$.

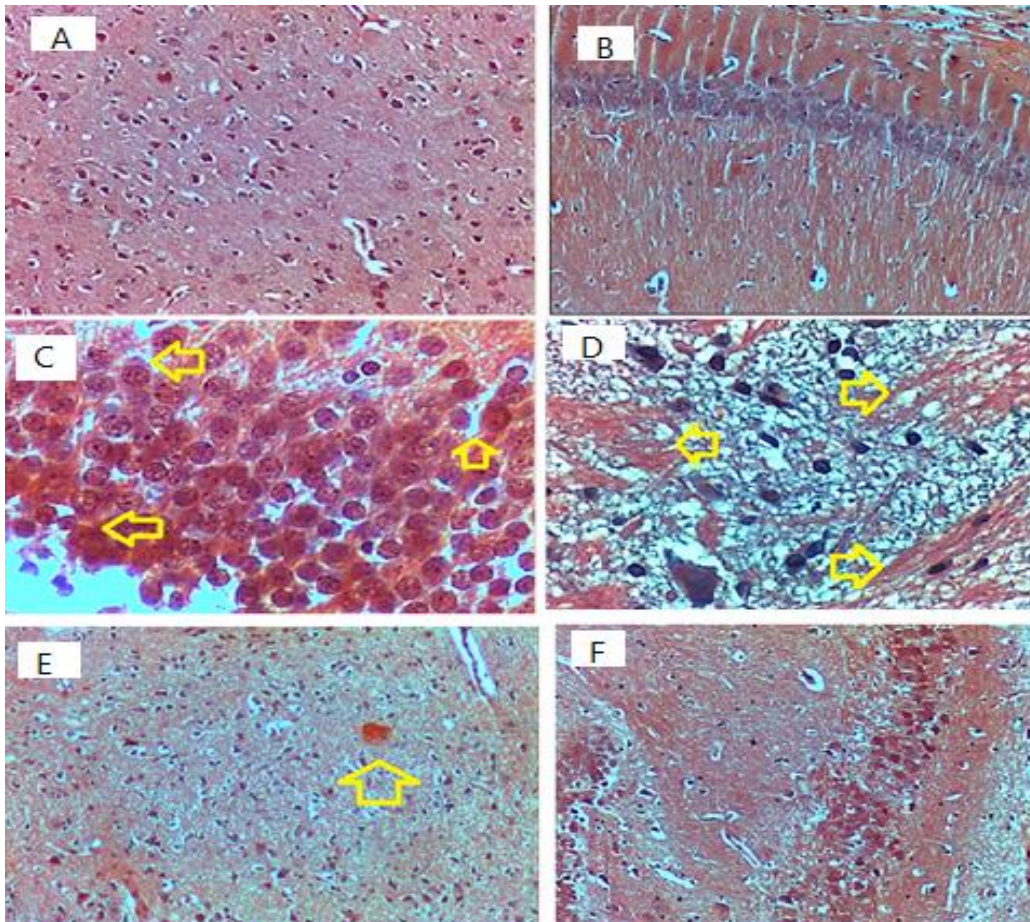
3. Results:

In **Figure 2 A&B**: Normal cerebral and hippocampus histological architecture. tissue section not shown any amyloid deposition. By using Congo red and Hematoxylin while in induced aluminum chloride rats group (**Figure 2 C& D**) massive depotion of amyloid protein (arrow) in cerebral parenchyma was observed as well as hippocampus,

Figure 2 E & F are AD-induced group rats and treated with chemical drug rivastigmine minor deposition of amyloid beta was observed in cerebral, in contrast the hippocampus did not show any amyloid, in

Figure 2 G & J : Photomicrograph of cerebrum of AD induced group rats and treated with 250 mg/kg of *Ocimum basilicum* :G/ Minor deposition of amyloid protein (arrow) in cerebral parenchyma was observed. Congo red and Hematoxylin. as well as Hippocampus (J) did not show any amyloid deposition. Congo red and Hematoxylin400x.

However, **Figure 2K&M:** Photomicrograph of hippocampus and cerebral of 500 mg/kg of *Ocimum basilicum* and Rivastigmine treated group rat did not show any amyloid deposition. Congo red and Hematoxylin. 400x.



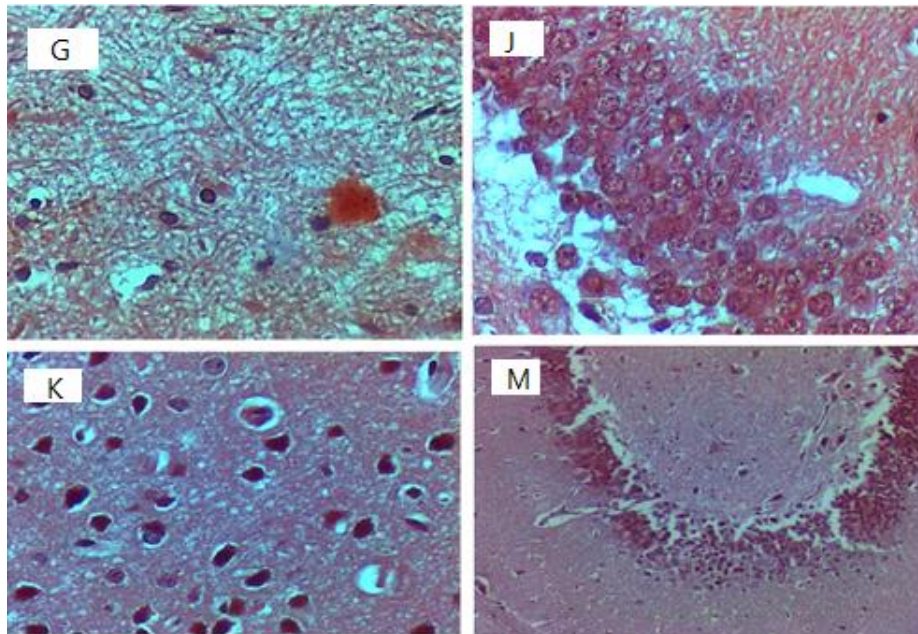


Figure 2: Photomicrograph of cerebrum of control negative group rat (A) and hippocampus of control negative group rat (B). : Photomicrograph of cerebrum of control positive group rat (C) Congo red and Hematoxylin and hippocampus of control positive group rat (D). Photomicrograph of cerebrum of Rivastigmine treated only group rat (E) Minor deposition of amyloid protein (arrow) in cerebral parenchyma was observed. Hippocampus of Rivastigmine treated only group rat (F). Photomicrograph of cerebrum of 250 mg/kg of *Ocimum basilicum* and Rivastigmine treated group rat (G). Minor deposition of amyloid protein (arrow) in cerebral parenchyma was observed AND Photograph of hippocampus of 250 mg/kg of *Ocimum basilicum* and Rivastigmine treated group rat (J). Hippocampus did not show any amyloid deposition. Photomicrograph of cerebrum of 500 mg/kg of *Ocimum basilicum* and Rivastigmine treated group rat (K). Cerebral tissue did not show any amyloid deposition and Photomicrograph of hippocampus of 500 mg/kg of *Ocimum basilicum* and Rivastigmine treated group rat (M). Hippocampus did not show any amyloid deposition. Congo red and Hematoxylin staining. 400x.

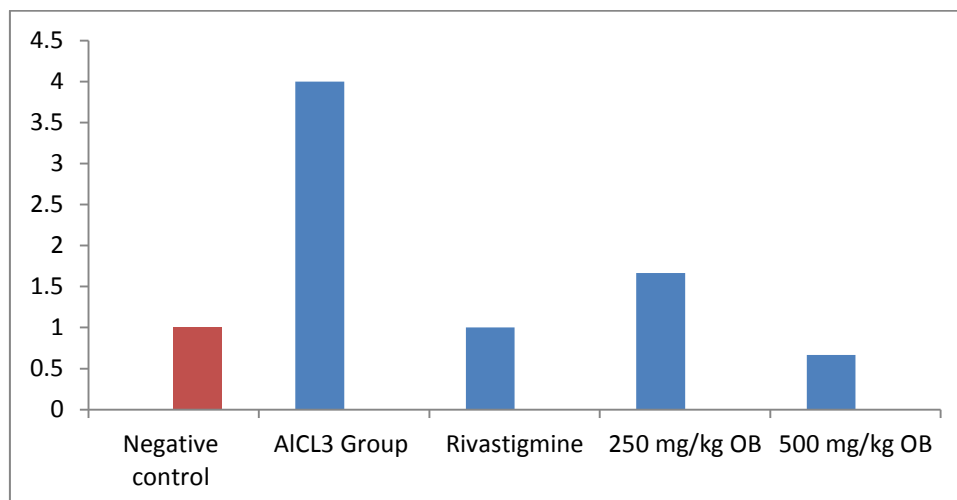


Figure 3: Showing amyloid scoring of Rats were induced with Alzheimer's disease and treated with Rivastgmine and 250 mg/kg OB and 500 mg/kg OB.

Discussion

Alzheimer's disease constitutes a complex problem with an increase in the number of patients. Most studies have shown that the cause of this disease is oxidative stress due to the imbalance between oxidative and antioxidant processes. There are a lot of mechanisms that lead to oxidative stress. The current study used aluminum chloride to induce disease and showed a decrease in SOD (Results are not shown), and this may be a result of the accumulation of hydrogen peroxide H₂O₂, which leads to oxidation of proteins, fats and thus oxidation, as a result of the presence of a high level of oxidant, which leads to the consumption of antioxidant (Bui & Nguyen, 2017).

A histological assessment demonstrated the creation of amyloid plaques in the AlCl₃ – treated groups showing the development of AD pathology, Therefore, it really difficult for antioxidants to supply a protection against free radicals with following progress of the pathological alterations that characterize the neurodegenerative illnesses (Wightman, et al. 2017).

Rivastigmine was used a drug for AD patients because it was shown to improve memory functions and stabilizing the patient's life. Treatment of AD group of rats with Rivastigmine exhibited an improvement in oxidative stress status and restore antioxidant defenses through the glutamergic mechanism of action (PORSTEINSSON et al. 2008). (Shah S, et al. 2006) Additionally, prevent the oxidative damage brought on by the A using specific acetylcholinesterase inhibitors. (XIAO XQ, et al. 2000).

Rivastigmine protects behavioral changes, restores antioxidant defense enzyme in brain.

These results were corresponding with the histopathological results in brain where, the amyloid accumulation are formed under the influence of AlCl₃ administration has been mostly not disappeared than AD group. Our results in agreement with other studies that indicated that Rivastigmine treatment recovers cognition, daily living activities by targeting a glutamergic mechanism resulting in reduction of oxidative status and restore of antioxidants defense (Yuan, et al. 2019)).

O. basilicum is well known as a plant medicine and it has been cultivates in different regions over the world (R. Kaur, Mehan, and others, 2015)).

It has been discovered that the plant's oil is helpful for treating psychological fatigue, colds, contractions, and rhinitis (Malik, et al. 2022).

However, there is no information on the chemical makeup of *Ocimum basilicum* leaves or their pharmacological effects on the central nervous system in particular for patients suffering from AD.

References:

- [1]- M.A. DeTure, D.W. Dickson, The neuropathological diagnosis of Alzheimer's disease, Mol. Neurodegener. 14 (2019) 1–18 2019 14:1, BioMed Central., doi: 10.1186/S13024-019-0333-
- [2]-]-Yuan, Ning Ning Cai, Cui Zan Wu, Ming Yue Su, Huan Xing Li, Min Lu, Jia Hong Neuroprotective effects of berberine in animal models of Alzheimer's disease: A systematic review of pre-clinical studies (2019). BMC Complementary and Alternative Medicine.

- [3]-Mahdy, K., Shaker, O., Wafay, H., Nassar, Y., Hassan, H., & Hussein, A. (2012). Effect of some medicinal plant extracts on the oxidative stress status in Alzheimer's disease induced in rats. *European Review for Medical and Pharmacological Sciences*, 16(SUPPL. 3), 31–42.
- [4]- (Mehan, S. et. al. (2015). Ameliorative Treatment with Ellagic Acid in Scopolamine Induced Alzheimer's Type Memory and Cognitive Dysfunctions in Rats. *Austin Journal of Clinical Neurology*, 2(6). www.austinpublishinggroup.com.
- [5]-Bui, T. T., & Nguyen, T. H. (2017). Natural product for the treatment of Alzheimer's disease. *Journal of Basic and Clinical Physiology and Pharmacology*, 28(5), 413–423. <https://doi.org/10.1515/jbcpp-2016-0147>
- [6]- Gong S, Miao YL, Jiao GZ, SunMJ, Li H, Lin J, Luo MJ, Tan JH (2015) Dynamics and correlation of serumcortisol and corticosterone under different physiological or stressful conditions in mice. *PLoS One* 10(2):e0117503.
- [7]- Joris J Hoelbeek, Jesper Kers, Eric J Steenbergen, Joris J T H Roelofs, Sandrine Florquin, Renal amyloidosis: validation of a proposed histological scoring system in an independent cohort, *Clinical Kidney Journal*, Volume 14, Issue 3, March 2021, Pages 855–862, <https://doi.org/10.1093/ckj/sfaa019>
- [8]-] Wightman, Emma L. - Potential benefits of phytochemicals against Alzheimer's disease.(2017) Proceedings of the Nutrition Society.
- [9]- PORSTEINSSON AP, GROSSBERG GT, MINTZER J, OLIN JT. Memantine MEM- MD-12 Study Group. Memantine treatment in patients with mild to moderate Alzheimer's disease already receiving a cholinesterase inhibitor: a randomized, doubleblind, placebo-controlled trial. *Curr Alzheimer Res*2008; 5: 83-89.
- [10] -SHAH S, REICHMAN WE. Treatment of Alzheimer's disease across the spectrum of severity. *Clin Interv Aging* 2006; 1: 131-142.
- [11]- XIAO XQ, WANG R, HAN YF, TANG XC. Protective effects of huperzine A on beta-amyloid (25–35) induced oxidative injury in rat pheochromocytoma cells. *Neurosci Lett* 2000; 286: 155-168.
- [12]-Kaur, R., Mehan, S. et. al. (2015). Ameliorative Treatment with Ellagic Acid in Scopolamine Induced Alzheimer's Type Memory and Cognitive Dysfunctions in Rats. *Austin Journal of Clinical Neurology*, 2(6). www.austinpublishinggroup.com
- [13]-N .Malik, s. Amber ,s. zahid. 2022Rosmarinus officinalis and Methylphenidate Exposure Improves Cognition and Depression and Regulates Anxiety-Like Behavior in AICl3-Induced Mouse Model of Alzheimer's Disease.